

## *Microsporum canis*

Worldwide dermatophyte

Natural reservoir = **dogs** and **cats**

Highly contagious

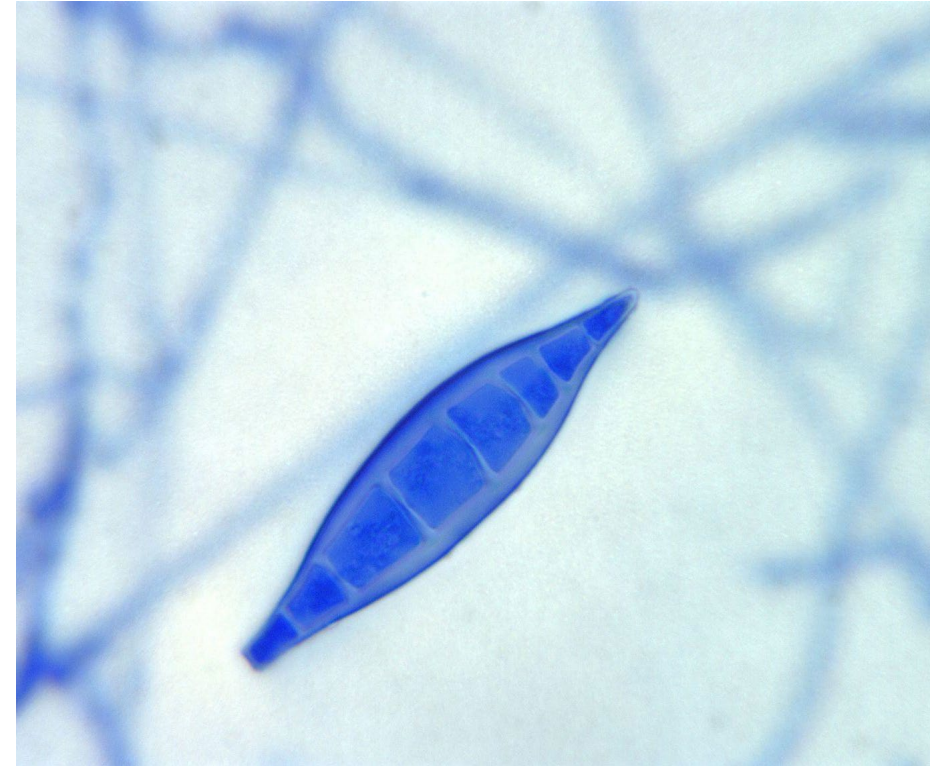
Causes **tinea capitis** and **tinea corporis**, esp in children

May see multifocal alopecia, scaling and circular lesions

Causes ectothrix infection ie involves the **outside** surface of the hair shaft

Fluoresces **bright yellow-green** under Wood's UV light

High rates of treatment failure



### ***M. canis***

*Microscopically:* **spindle-shaped** macroconidia, 6-15 celled, thick outer cell wall with thin inner septae; septate hyphae.

*Macroscopically:* Grows rapidly at 25°C, dense cottony, white to yellow on top; deep yellow/orange reverse.